

X-Linked Cone Dysfunction Syndrome with Myopia and Protanopia

Michel Michaelides, BSc, MRCOphth,^{1,2} Samantha Johnson, BSc, PhD,¹ Keith Bradshaw, BSc, PhD,³ Graham E. Holder, BSc, PhD,² Matthew P. Simunovic, BSc, PhD,⁴ John D. Mollon, DSc, FRS,⁴ Anthony T. Moore, MA, FRCOphth,^{1,2} David M. Hunt, BSc, PhD¹

Purpose: To perform a detailed clinical, psychophysical, and molecular assessment of members of 4 families with an unusual X-linked cone dysfunction syndrome associated with myopia.

Participants: Affected and unaffected members of 4 British nonconsanguineous families.

Methods: Subjects underwent both detailed clinical examination and psychophysical testing. After informed consent was obtained, blood samples were taken for DNA extraction, and molecular genetic analysis was performed. The strategy for molecular analysis was to amplify the coding regions of the long and middle wavelength-sensitive cone opsin genes and the upstream locus control region by polymerase chain reaction and to examine these fragments for mutations by sequencing of DNA.

Results: The phenotype was almost identical in all 4 families, consisting of moderate to high myopia, astigmatism, moderately reduced acuity, and normal fundi. Electroretinography showed abnormal cone but normal rod responses. Psychophysical testing showed a selective impairment of long cones in combination with well-preserved middle cone and short cone function. There was no evidence to suggest that the phenotype was progressive. Molecular analysis of the X-linked opsin gene array in the 4 families indicated that affected males have inherited the same X-chromosome from their mother. In 2 families, a long/middle hybrid gene was detected. In a third family, the commonly described deleterious Cys203Arg amino acid substitution was identified in both the long and middle opsin genes. In the fourth family, the only abnormality was absence of a middle opsin exon 2; the cause of the protanopia in this family is uncertain.

Conclusions: The X-linked cone dysfunction syndrome associated with myopia and dichromacy described here has many similarities to Bornholm eye disease, a condition previously mapped to Xq28. Except for the Cys203Arg substitution in one family, no alterations in the opsin gene array were identified that could underlie the cone dysfunction. It is therefore possible that the cone dysfunction may have a genetic origin different from that of the dichromacy. *Ophthalmology* 2005;112:1448–1454 © 2005 by the American Academy of Ophthalmology.



The cone and cone-rod dystrophies form part of a heterogeneous group of retinal dystrophies. The main clinical features of cone dystrophies are reduced visual acuity (VA), dyschromatopsia, photophobia and often nystagmus. Cone dystrophies have been described with autosomal dominant,

autosomal recessive, or X-linked patterns of inheritance.^{1,2} They may be progressive or stationary; the latter group includes the well-characterized cone dysfunction syndrome of rod monochromatism, a recessive disorder in which there are few or no functioning cones,^{3,4} and blue cone monochromatism, an X-linked disorder in which there are only 2 functional classes of photoreceptor (rods and short cones).^{5–7}

In this report, we describe 4 families with X-linked inheritance of a stationary cone dysfunction syndrome characterized by myopia, moderate visual loss, and a protan color vision abnormality. The involvement of a protan color vision abnormality with progressive cone dystrophy has been reported previously.^{8,9} However, it is unusual because dichromacy, which arises from either the loss of long or middle opsin gene sequences,¹⁰ or from the presence of a missense mutation in the opsin gene with consequent loss of function,^{11,12} has not been associated with cone dystrophy in extensive studies of dichromats.^{10,13,14} Nevertheless, opsin gene mutations are seen in the stationary cone dysfunction syndrome, blue cone monochromatism.^{5–7} We have

Originally received: December 5, 2004.

Accepted: February 21, 2005.

Manuscript no. 2004-369.

¹ Institute of Ophthalmology, University College London, London, United Kingdom.

² Moorfields Eye Hospital, London, United Kingdom.

³ Department of Ophthalmology, Addenbrookes Hospital, Cambridge, United Kingdom.

⁴ Department of Experimental Psychology, University of Cambridge, Cambridge, United Kingdom.

Supported by a grant from the Guide Dogs for the Blind Association, Reading, United Kingdom.

There is no conflict of interest.

Correspondence to Prof David M. Hunt, Institute of Ophthalmology, University College London, 11-43 Bath Street, London, EC1V 9EL, United Kingdom. E-mail: d.hunt@ucl.ac.uk.

therefore examined the X-linked long (L) and middle (M) opsin genes in the affected members of our 4 families to determine how far mutations in these genes may underlie the cone dysfunction. In addition, our families share many features with Bornholm eye disease (BED), a condition characterized by myopia, deuteranopia, and cone dysfunction, which has been mapped to Xq28, a chromosomal region that includes the opsin gene array.^{15,16}

Patients and Methods

The pedigrees of all 4 families showed only males affected, and an absence of male-to-male transmission could be established in 2 of the families, a pattern of inheritance consistent with X-linkage. Affected and unaffected members of all 4 families were examined clinically and underwent extensive psychophysical testing. After informed consent was obtained, blood samples were taken, genomic DNA was isolated from whole blood using an extraction kit (Tepnel Life Sciences, Manchester, United Kingdom), and molecular genetic analysis was performed.

Clinical Assessment

A full medical history was taken and ophthalmological examination performed in all affected subjects. Color fundus photography and electrophysiological testing were undertaken, including electroretinography and electro-oculography, according to the protocols recommended by the International Society for Clinical Electrophysiology of Vision.^{17,18} Color vision testing included the use of Hardy, Rand, and Rittler (HRR) plates (American Optical Co., New York, NY); SPP2 plates for acquired color deficiency; Farnsworth–Munsell 100-hue test; Farnsworth D-15 test; Mollon–Reffin minimal test¹⁹; a computerized color vision test; and anomaloscopy. The computerized color vision test, which allows measurement of color discrimination along tritan, deutan, and protan axes, has been described in detail previously (J Physiol 414:5P, 1989).²⁰ The Farnsworth–Munsell 100-hue, Farnsworth D-15, and Mollon–Reffin tests were all performed under CIE standard illuminant C from a MacBeth Easel lamp (MacBeth Corp., Newburgh, NY).

Molecular Genetic Analysis

In each family, affected males and female carriers were analyzed. Independent polymerase chain reactions (PCRs) were set up to amplify the locus control region (LCR) and all exons of the L and M opsin genes from genomic DNA. Primer pairs that would coamplify both long and middle opsin exonic sequences were designed within each intron approximately 50 base pairs from the intron–exon junction so that the whole of each exon plus some flanking intron sequence was amplified. The design of these primers was based on the published sequence of the long and middle opsin genes.²¹ Fifty-microliter PCR reactions were performed as follows: $\times 1$ ammonium buffer, 1-mmol/l magnesium chloride, 200 μ mol/l each deoxyribonucleotide triphosphate, 10 pmol each of sense and antisense primers, 200 ng to 1 μ g of DNA, 1 U of *BioTaq*, and distilled water to a total volume of 50 μ l—with the exception that the concentrations of magnesium chloride used in the LCR, exon 3, and exon 6 amplification reactions were optimized at 0.5 mmol/l, 0.5 mmol/l, and 2 mmol/l, respectively—and with annealing at the exon-specific temperatures listed in Table 1 (available at <http://aaojournal.org>). Polymerase chain reaction products were visualized by electrophoresis using low-melting

temperature agarose gel. Target products were then excised and eluted. Mutation analysis was carried out by directly sequencing PCR products using PCR primers and a cycle sequencing kit (Perkin Elmer, Wellesley, MA). Alternatively, PCR fragments were cloned into the vector pGEM-T easy (Promega, Southampton, United Kingdom) and sequenced using pGEM-T easy primers. In both cases, sequencing products were precipitated and analyzed on an ABI 373A automated DNA sequencer (Applied Biosystems, Foster City, CA).

Results

Clinical Assessment

The clinical and psychophysical results in affected subjects are summarized in Table 2 (available at <http://aaojournal.org>). These subjects displayed myopia (moderate to high), astigmatism, reduced VA (6/12–6/36), protanopia, and normal fundi (myopic changes and tilted optic discs were seen in some individuals). No nystagmus was observed. Electroretinograms of affected males demonstrated normal rod function but a marked attenuation of cone function (Fig 1). There has been no clinical evidence of progression in any subjects to date. In family A, an older affected family member was available for testing; his clinical findings were entirely comparable to those of both of his grandchildren, thereby suggesting that this cone dysfunction syndrome with myopia and dichromacy is stationary.

Family A has 2 affected brothers who originally presented in the first decade of life with poor VA (Fig 2). Patient A1(III:1) was a 15-year-old boy with reduced VA (6/12 in both eyes) who was found to have a color vision defect, high myopia and astigmatism (right eye, $-9.50/-3.50 \times 5$; left eye, $-10.00/-2.50 \times 5$), and a divergent squint. Fundus examination was normal. Electrophysiological testing revealed abnormal cone responses but normal rod function. Patient A2(III:2) was his 8-year-old brother, who presented with reduced VA (6/18 in both eyes) and was also found to have a color vision defect and myopia with an astigmatic error (right eye, $-3.50/-3.50 \times 5$; left eye, $-3.00/-4.00 \times 180$). Fundus examination revealed a myopic fundus but was otherwise unremarkable. Electroretinography showed evidence of generalized cone dysfunction with normal rod responses. Patient A3(I:1) was their 67-year-old maternal grandfather, who had suffered with poor vision since childhood and had a VA of 6/12 in both eyes with a myopic correction (right eye, $-2.00/-3.00 \times 10$; left eye, $-2.50/-2.50 \times 120$).

Only A1 and A2 were amenable for detailed psychophysical testing. A1 displayed a protanopic Rayleigh match with both eyes. D-15 (Fig 3) and computerized testing also revealed protan color deficiency. The Mollon–Reffin minimal test revealed normal tritan color discrimination and a red–green defect in each eye. Testing of A2 with HRR plates revealed red–green color deficiency with predominantly protan errors, while the Mollon–Reffin minimal test revealed normal tritan color discrimination and a red–green defect in both eyes. Patient A3 also showed a protan color vision defect when tested with HRR plates. There has been no deterioration in vision of either brother since presentation 8 years ago, and because their grandfather's vision has remained stable throughout life, it suggests that the cone dysfunction is stationary.

Family B is comprised of 2 affected brothers, B1 and B2, who both presented in the first decade of life with poor VA. Patient B1 was an 18-year-old man with VA of 6/18 in each eye with his myopic correction (right eye, $-6.00/-2.00 \times 15$; left eye, $-6.00/-2.50 \times 160$). Fundus examination was normal. Electroretinography showed evidence of generalized cone dysfunction with normal rod responses. Patient B2 was his 22-year-old brother with poor

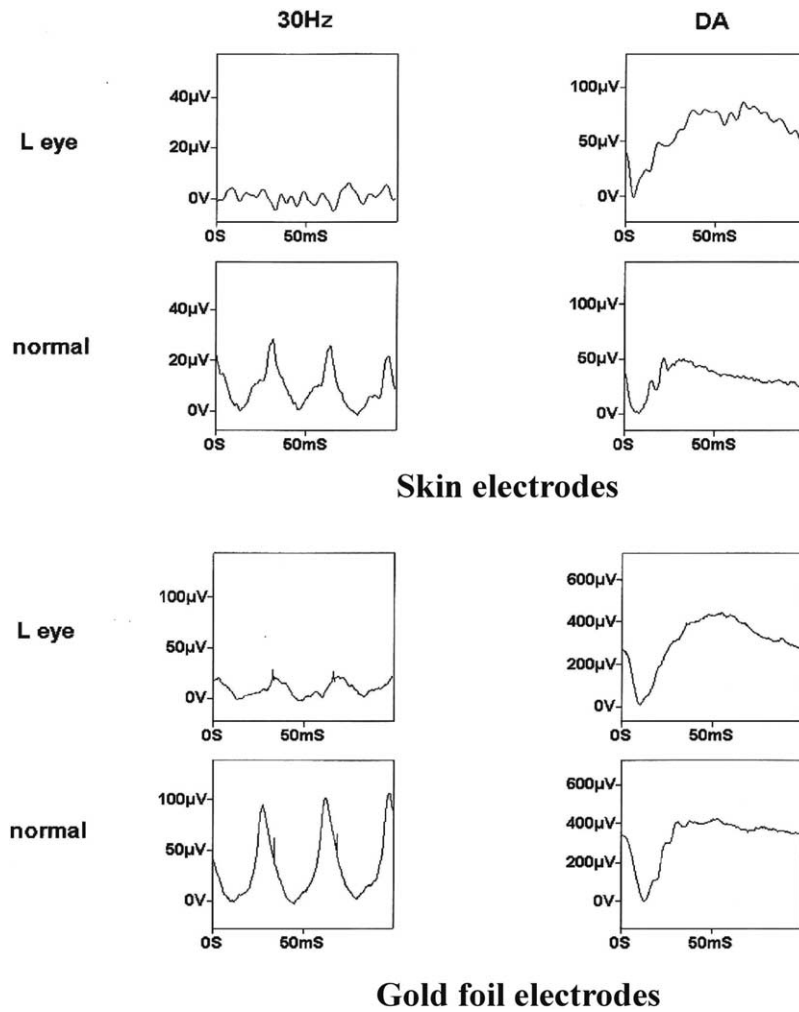


Figure 1. Electoretinograms of 2 affected males from family A recorded using either skin or gold foil electrodes. The left-hand column shows cone responses for recordings at 30-hertz (30Hz) flicker stimulation, and the right-hand column shows dark-adapted (DA) mixed rod–cone (maximal) responses. Cone responses are markedly reduced, whereas rod responses are within normal limits (maximal response a-wave amplitude being a measure of rod photoreceptor function). L = left; mS = milliseconds; μV = microvolts.

VA (6/12 in both eyes), who was found to have a color vision defect, myopia, and astigmatism (right eye, $-3.00/-3.00 \times 25$; left eye, $-2.50/-2.50 \times 130$). Fundoscopy revealed normal fundi, other than tilted discs. Electoretinography showed evidence of generalized cone dysfunction with normal rod function.

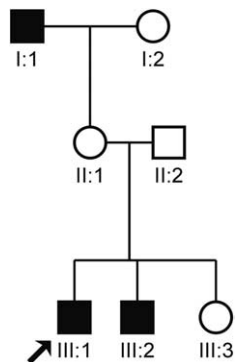


Figure 2. Family A pedigree.

Both brothers could obtain color matches with the anomaloscope over the entire red–green range of the instrument; the yellow brightness settings were consistent with a diagnosis of protanopia. Both brothers also displayed a protan ordering on the D-15 test. On computerized color vision testing, both brothers displayed discrimination ellipses that were oriented tightly along a protan axis. To date there has been no deterioration in VA since presentation 9 years ago. Both parents of the 2 brothers were also tested and showed normal color vision.

Family C has 3 affected brothers, C1, C2, and C3, who all presented in the first decade of life with poor VA and mild photophobia. Patient C1, a 7-year-old boy with poor VA (6/36 in the right eye and 6/24 in the left eye), was found to have a color vision defect, myopia, and astigmatism (right eye, $-3.00/-2.50 \times 30$; left eye, $-3.25/-1.25 \times 165$). Fundoscopy revealed myopic fundi with tilted optic discs. Electoretinography showed evidence of generalized cone dysfunction with normal rod function. Patient C2, a 5-year-old boy with poor VA (6/12 in both eyes), was found to have a color vision defect, myopia, and astigmatism (right eye, $-2.00/-1.50 \times 180$; left eye, $-2.00/-1.00 \times 180$). Fundoscopy revealed normal fundi. Electoretinography showed evidence of

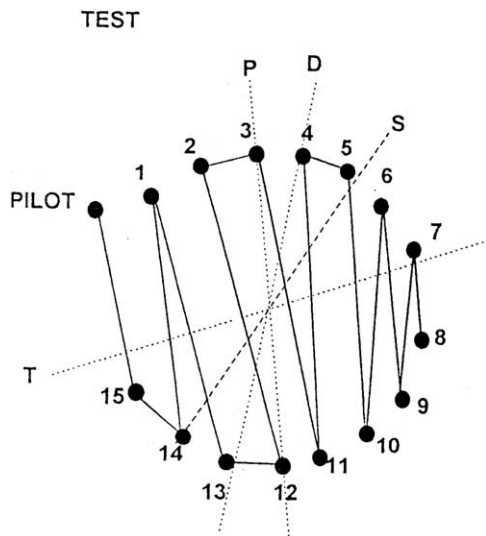


Figure 3. Subject A1's Farnsworth D-15 test. The 16 filled circles represent colored chips that, when ordered by an individual with normal color vision, form a color circle of pastel hues. Red/green color vision-deficient subjects make characteristic crossings from one side of the color circle to the other. Here, individual A1 makes crossings along the confusion pattern for a protanopic dichromat. D = deutan; P = protan; S = scotopic; T = tritan.

significant loss of cone function with normal rod responses. Patient C3 was a 4-year-old boy with poor VA (6/18 in both eyes), myopia, and astigmatism (right eye, $-2.50/-2.25 \times 180$; left eye, $-2.50/-2.25 \times 180$). Fundoscopy revealed normal fundi. Electroretinography showed abnormal cone function with normal rod responses.

The young age of the 3 affected male brothers in this pedigree limited the range of psychophysical testing. The 2 tested males, C1 and C2, both displayed good discrimination along the tritan axis of the Mollon-Reffin test. However, both showed significantly elevated thresholds for red-green discrimination, and HRR testing also provided evidence of a protan color deficit. Their sister and mother were found to have normal vision and normal color vision.

To date, there has been no deterioration in VA since presentation 4 years ago.

In family D, patient D1 was a 7-year-old boy who presented with VAs of 6/24 in the right eye and 6/18 in the left eye. He was found to have a color vision defect, myopia, and astigmatism (right eye, $-4.75/-1.00 \times 80$; left eye, $-4.75/-1.00 \times 120$). Fundoscopy revealed myopic fundi with tilted optic discs (Fig 4). Electroretinography showed evidence of generalized cone dysfunction with normal rod responses. The patient's maternal grandfather and a male cousin of his mother were both color-blind and suffered from reduced VA from a young age, not fully corrected by spectacles. Neither was willing to undergo psychophysical testing.

On the City University color vision test and HRR plates, a red-green deficiency was detected in patient D1, with mainly a protan defect. On the D-15, he showed a predominantly protan sequence of errors with each eye. At the anomaloscope, he showed a protan spectral sensitivity, and on computerized color testing his discrimination ellipse was oriented in a protan direction. His mother was found to have entirely normal color vision.

Molecular Genetics

Because all patients showed clear evidence of protanopia, experiments were undertaken to establish whether novel mutations in the L and M opsin gene array on the X chromosome were responsible for the color vision defect and cone dysfunction.

The activity of the opsin gene array is controlled by the LCR, which is approximately 3.5 kilobases upstream of the L gene, with the M gene a further 24 kilobases downstream.^{21,22} This tandem array may be extended, however, by additional M or hybrid L/M genes or may be contracted to a single L or M gene in the case of deuteranopia or protanopia, respectively,^{10,21} or to a single hybrid gene where the nature of the color vision defect will depend on the particular combination of L and M gene exons. The sequence differences that differentiate the 6 exons of the L and M opsin genes are listed in Table 3 (available at <http://aaojournal.org>). Note that exons 1 and 6 of the 2 genes are identical. A number of studies have demonstrated that the 30-nm spectral shift between the L and M pigments is almost entirely due to amino acid differences at only 3 sites: 180 (exon 3) and 277 and 285 (exon 5).^{23,24}

Polymerase chain reaction products amplified from genomic DNA using either primer pairs flanking the LCR region or primer

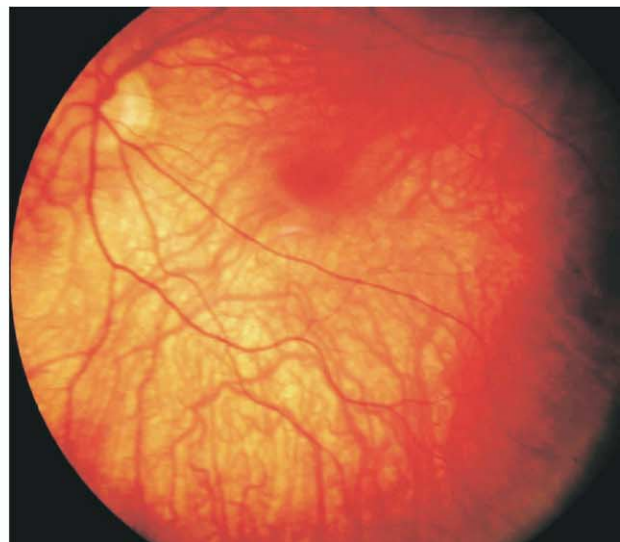
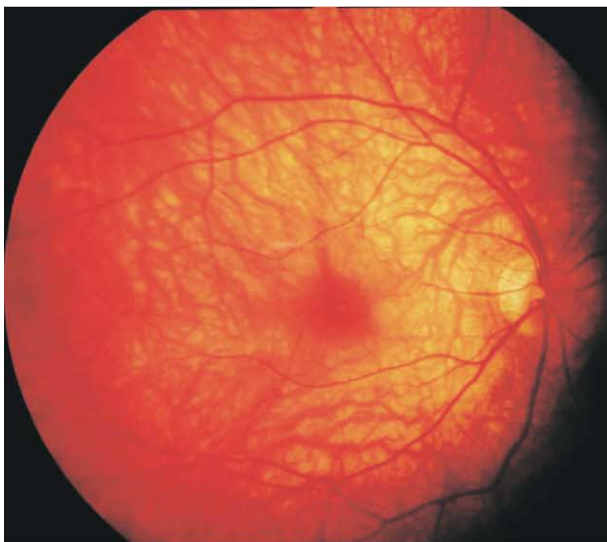
Figure 4. Myopic fundi with tilted optic discs.

pairs designed to amplify both the L and M genes were directly sequenced. In family A, this showed the presence of the LCR and both L and M opsin genes in subjects A1, A2, and A3. Sequence data for exon 4 showed the presence of a T→C nucleotide transition at position 648 in all affected family members. This change encodes a Cys203Arg substitution in the opsin protein molecule, a change that is known to disrupt opsin folding,²⁵ and is responsible for the loss of gene function in blue cone monochromacy.⁵⁻⁷ Two approaches were taken to localize this mutation to either an L or an M opsin gene. Firstly, exon 4 PCR products were cloned into pGEM-T easy plasmid vector and sequenced using vector primers, and secondly, by using the nucleotide differences between L and M opsin genes in exon 4 to design primers to amplify specifically either L or M opsin exon 4 (L Ex4R and M Ex4R in Table 1 [available at <http://aaajournal.org>]). In the latter case, the PCR products were directly sequenced. The combined results demonstrated the presence of both wild-type and mutant variants of exon 4 in both L and M opsin genes. This would imply that affected members of family A have at least 4 opsin genes but that the only functional pigment produced is from a normal copy of the M gene, thereby explaining the protanopia in this family.

Patients B1 and B2 in family B both possessed an intact LCR and the full complement of L opsin gene exons. There was, however, no evidence of an M opsin gene exon 2, indicating that a hybrid gene is present that is composed of exons 1 to 2 from the L gene and exons 3 to 6 from the M gene. This gene would be expected to encode a pigment that is spectrally identical to a standard M gene. However, the presence of an L gene is inconsistent with the protanopia seen in the affected family members; what cannot be established from our data is whether an L gene is expressed, and the color vision defect would suggest that it is not.

Sequence data from family C indicated that the LCR and all the L and M gene exons were present, except for L gene exon 5. This would indicate that at least 2 opsin genes are present in the array in this family, a normal M and a hybrid L/M gene. The protanopia is consistent with the expression of ≥ 1 of these genes, because both would give a pigment with a λ_{\max} around 535 nm.

Sequence analysis of PCR products obtained from family D demonstrated that exons 3 to 5 of the L gene are absent from the gene array of the affected proband in family D, suggesting the presence of a hybrid L/M gene. This is again consistent with protanopia if the gene(s) in the array lack exons 3 and 5 of the L gene that encode key residues for spectral tuning.

With the exception of the Cys203Arg substitution in family A, none of the opsin gene sequences identified mutations that would account for the cone dysfunction seen in all these families.

X Linkage

The alterations in the L and M genes described for the 4 families were present in all affected members and were shown to be carried by obligate carrier females in each family but not in unaffected members. Because the cone dysfunction is seen only in male members of the families with protanopia, which in families A and D is extended to different generations, this would indicate that the cone dysfunction shares the same X-linked inheritance pattern.

Discussion

The affected members of the families described in this study have a very similar stationary cone dysfunction syndrome characterized by moderate to high myopia, astigmatism, moderately reduced VA not improved by full spectacle correction, normal or myopic fundi, and evidence of a

selective impairment of the L cones on psychophysical testing. There is also clear evidence for X-linked inheritance. Nystagmus was not present in affected subjects.

The association of protanopia with cone dysfunction indicates a potential role for opsin gene mutations in the etiology of the disorder. However, although the molecular analysis of the opsin gene array on the X chromosome revealed changes that clearly are consistent with the protanopia in 3 of the families (A, C, and D), in each case the changes differ. The only opsin gene mutation that could potentially account for the cone dysfunction is the Cys203Arg substitution in family A, a mutation that has been shown to impair the folding and stability of opsin photopigment.²⁵ However, the presence of normal M and L opsin genes in an expanded opsin gene array in this family makes it uncertain whether this change is responsible for the disorder. In the other 3 families, there are no changes in the opsin gene array that could account for the cone dysfunction.

There has been no further visual deterioration in any of our patients, suggesting that the disorder in these families is stationary. Patients with progressive cone dystrophies are not usually symptomatic until late childhood or early adult life,²⁶ whereas, in our families, presentation was within the first decade of life, with patients often symptomatic in the first few years of life. In the progressive cone dystrophies, photophobia is a prominent early symptom, often associated with nystagmus.^{1,2} In contrast, our patients did not have nystagmus, and photophobia was mild. Progressive cone dystrophies usually show evidence of retinal degeneration in the form of a bull's-eye maculopathy on funduscopy, although, in some cases, there may be only minor macular retinal pigment epithelial atrophy and pigmentation. In all affected members of our families, fundus appearance was normal, other than myopic fundi in some individuals. Progressive cone dystrophies usually show a progressive loss of color vision, with all 3 classes of cone photoreceptors affected to the same or similar extents, thus producing color vision defects along all 3 color axes up to total achromatopsia.^{1,2} Exceptions to this include cases in which there is a predominant involvement of L cones leading to a protan phenotype,^{8,9} but unlike our family members, nystagmus is generally present, with variable or no refractive error.

A constant feature of the disorder in our families was myopia. Myopia can be inherited either as an autosomal recessive or as an X-linked trait, and in the latter case, it is a well-known component of congenital stationary night blindness and X-linked retinitis pigmentosa.^{27,28} Another example of X-linked myopia has been reported in a large 5-generation family that had its origins on the Danish island of Bornholm. The syndrome has therefore been named Bornholm eye disease.^{15,16} In this family, the syndrome manifests as myopia combined with astigmatism, and impaired VA. Additional signs are moderate optic nerve head hypoplasia, thinning of the retinal pigment epithelium in the posterior pole with visible choroidal vasculature, and reduced cone electroretinography responses as the most constant finding. Importantly, all affected members in the BED family are dichromats, although in this case it is deuteranopia that is present. Linkage analysis mapped the BED locus to Xq28, in the same chromosomal region, therefore, as the

L/M opsin gene array. More recently, a second family with BED, again of Danish origin, has been mapped to Xq28, but significantly in this case, the cone dysfunction is associated with protanopia.²⁹

Our families share many characteristics with this latter BED pedigree—namely, X-linked inheritance, reduced cone electroretinograms, myopia with astigmatism, poor VA, protanopia, and the absence of nystagmus. It seems likely, therefore, that the disorder described in our families is the same stationary cone dysfunction syndrome as reported in the Danish kindreds. If so, because BED was mapped to Xq28, the failure to find mutations in the opsin gene array in most of our families (and the Danish families²⁹) to account for the cone dysfunction raises the possibility that the cone dysfunction component of the disorder may be ascribed to an adjacent but separate locus. To date, however, the only cone dystrophy (COD2) that maps to an adjacent region (Xq27) displays a different phenotype.³⁰

We have been unable to identify any patients with a similar X-linked cone dysfunction syndrome without dichromacy, so it seems that this form of cone dysfunction is seen only in association with dichromacy. The different molecular explanations for the dichromacy in our 4 families and in the 2 Danish kindreds preclude a founder effect as the basis for this association, and linkage disequilibrium in this chromosomal region seems unlikely, given the high frequency of crossing over within the opsin gene array in the generation of numerical variants of M and L genes³¹ and gene hybrids.¹⁰ The existence of other opsin array alterations such as deletions was shown not to underlie the cone dysfunction in the Danish kindreds,²⁹ but it is possible that there is an as yet unidentified mutation within the opsin promoter regions that results in an altered level of pigment production followed by cell death. However, an alternative and intriguing explanation is that the cone dysfunction arises from a mutation in a gene that causes cone dysfunction only when expressed in dichromats.

If mutations within the opsin gene array are not directly responsible for the cone dysfunction described here and in BED, then mutations in an adjacent locus must be involved that simultaneously cause cone dysfunction and dichromacy. A mechanism involving loss of pigment synthesis in one or other cone classes could be envisaged, with the cone dysfunction associated with either protanopia or deuteranopia, depending on which cone class remained functional.

References

1. Michaelides M, Hunt DM, Moore AT. The cone dysfunction syndromes. *Br J Ophthalmol* 2004;88:291–7.
2. Simunovic MP, Moore AT. The cone dystrophies. *Eye* 1998;12:553–65.
3. Johnson S, Michaelides M, Aligianis IA, et al. Achromatopsia caused by novel mutations in both *CNGA3* and *CNGB3* [article online]. *J Med Genet* 2004;41:e20. Available at: <http://jmg.bmjournals.com/cgi/content/full/41/2/e20>. Accessed February 21, 2005.
4. Wissinger B, Gamer D, Jägle H, et al. *CNGA3* mutations in hereditary cone photoreceptor disorders. *Am J Hum Genet* 2001;69:722–37.
5. Michaelides M, Johnson S, Simunovic MP, et al. Blue cone monochromatism: a phenotype and genotype assessment with evidence of progressive loss of cone function in older individuals. *Eye* 2005;19:2–10.
6. Nathans J, Davenport CM, Maumenee IH, et al. Molecular genetics of human blue cone monochromacy. *Science* 1989;245:831–8.
7. Ayyagari R, Kakuk LE, Bingham EL, et al. Spectrum of color gene deletions and phenotype in patients with blue cone monochromacy. *Hum Genet* 2000;107:75–82.
8. Reichel E, Bruce AM, Sandberg MA, Berson EL. An electroretinographic and molecular genetic study of X-linked cone degeneration. *Am J Ophthalmol* 1989;108:540–7.
9. Kellner U, Sadowski B, Zrenner E, Foerster MH. Selective cone dystrophy with protan genotype. *Invest Ophthalmol Vis Sci* 1995;36:2381–7.
10. Deeb SS, Lindsey DT, Hibiya Y, et al. Genotype-phenotype relationships in human red/green color-vision defects: molecular and psychophysical studies. *Am J Hum Genet* 1992;51:687–700.
11. Winderickx J, Battisti L, Motulsky AG, Deeb SS. Selective expression of human X chromosome-linked green opsin genes. *Proc Natl Acad Sci U S A* 1992;89:9710–4.
12. Ueyama H, Kuwayama S, Imai H, et al. Novel missense mutations in red/green opsin genes in congenital color-vision deficiencies. *Biochem Biophys Res Commun* 2002;294:205–9.
13. Neitz M, Neitz J, Jacobs GH. Genetic basis of photopigment variations in human dichromats. *Vision Res* 1995;35:2095–103.
14. Jagla WM, Jagle H, Hayashi T, et al. The molecular basis of dichromatic color vision in males with multiple red and green visual pigment genes. *Hum Mol Genet* 2002;11:23–32.
15. Haim M, Fledelius HC, Skarsholm D. X-linked myopia in a Danish family. *Acta Ophthalmol (Copenh)* 1988;66:450–6.
16. Schwartz M, Haim M, Skarsholm D. X-linked myopia: Bornholm eye disease. Linkage to DNA markers on the distal part of Xq. *Clin Genet* 1990;38:281–6.
17. Marmor MF, Holder GE, Seeliger MW, Yamamoto S. International Society for Clinical Electrophysiology of Vision. Standard for clinical electroretinography (2004 update). *Doc Ophthalmol* 2004;108:107–14.
18. Marmor MF, Zrenner E. Standard for clinical electro-oculography. International Society for Clinical Electrophysiology of Vision. *Arch Ophthalmol* 1993;111:601–4.
19. Mollon JD, Astell S, Reffin JP. A minimalist test of colour vision. In: Drum B, Moreland JD, Serra A, eds. *Colour Vision Deficiencies X: Proceedings of the Tenth Symposium of the International Research Group on Colour Vision Deficiencies, Held in Cagliari, Italy, 25-28 June 1989*. Dordrecht, The Netherlands: Kluwer Academic Publishers; 1991:59–67. *Documenta Ophthalmologica. Proceedings Series. Vol. 54*.
20. Regan BC, Reffin JP, Mollon JD. Luminance noise and the rapid determination of discrimination ellipses in colour deficiency. *Vision Res* 1994;34:1279–99.
21. Nathans J, Thomas D, Hogness DS. Molecular genetics of human colour vision: the genes encoding blue, green, and red pigments. *Science* 1986;232:193–202.
22. Dulai KS, von Dornum M, Mollon JD, Hunt DM. The evolution of trichromatic color vision by opsin gene duplication in New World and Old World primates. *Genome Res* 1999;9:629–38.
23. Asenjo AB, Rim J, Oprian DD. Molecular determinants of human red/green color discrimination. *Neuron* 1994;12:1131–8.
24. Merbs SL, Nathans J. Absorption spectra of the hybrid pig-

- ments responsible for anomalous color vision. *Science* 1992;258:464–6.
25. Kazmi MA, Sakmar TP, Ostrer H. Mutation of a conserved cysteine in the X-linked cone opsins causes color vision deficiencies by disrupting protein folding and stability. *Invest Ophthalmol Vis Sci* 1997;38:1074–81.
 26. Sloan LL, Brown DJ. Progressive retinal degeneration with selective involvement of the cone mechanism. *Am J Ophthalmol* 1962;54:629–41.
 27. Musarella MA, Weleber RG, Murphy WH, et al. Assignment of the gene for complete X-linked congenital stationary night blindness (*CSNBI*) to Xp11.3. *Genomics* 1989;5:727–37.
 28. Kaplan J, Pelet A, Martin C, et al. Phenotype-genotype correlations in X linked retinitis pigmentosa. *J Med Genet* 1992; 29:615–23.
 29. Young TL, Deeb SS, Ronan SM, et al. X-linked high myopia associated with cone dysfunction. *Arch Ophthalmol* 2004;122: 897–908.
 30. Bergen AA, Pinckers AJ. Localization of a novel X-linked progressive cone dystrophy gene to Xq27: evidence for genetic heterogeneity. *Am J Hum Genet* 1997;60:1468–73.
 31. Drummond-Borg M, Deeb SS, Motulsky AG. Molecular patterns of X chromosome-linked color vision genes among 134 men of European ancestry. *Proc Natl Acad Sci U S A* 1989;86:983–7.

Table 1. Primers for the Amplification of the Locus Control Region (LCR) and Exons 1 to 6 of Long (L) and Middle (M) Opsin Genes

Primer Name	Sequence	Annealing Temperature (°C)	Product Size (Base Pairs)
LCR1+	5'-ggcaaatggccaaatggt-3'	49	884
LCR1-	5'-ccatgctatttgaagcc-3'		
L/M.Ex1F	5'-ggtgggaggaggagtctaa-3'	64	334
L/M.Ex1R	5'-ggtggcccccagtgccagcc-3'		
L/M.Ex2F	5'-ggtatagacagcggtgctg-3'	60	400
L/M.Ex2R	5'-gtgaatgagtgttccgcc-3'		
L/M.Ex3F	5'-gtctaagcaggacagtggaagcttgcctt-3'	60	302
L/M.Ex3R	5'-taaggtcacagagtctgacc-3'		
L/M.Ex4F	5'-acaaacccaccagtggtg-3'	58	340
L/M.Ex4R	5'-aggagtctcagtgactcat-3'		
L/M.Ex5F	5'-cctctcctcctccccacaac-3'	62	402
L/M.Ex5R	5'-caggtgggcccactca-3'		
L/M.Ex6F	5'-agggaaggtctggcagcta-3'	60	283
L/M.Ex6R	5'-gataaattacatttttacaggg-3'		
L Ex4R	5'-atgatgatagcagtgaggat-3'	56	121
M Ex4R	5'-acgatgatgctgagtgggt-3'	56	121

Table 2. Clinical and Psychophysical Findings

Patient	Age (yrs)	Refractive Error	Visual Acuity	D-15 Test	Mollon-Reffin Minimal Test
A1	15	-9.50/-3.50 ×5	R, 6/12	Protan	P (4), D (3), T (1)
		-10.00/-2.50 ×5	L, 6/12	Protan	P (4), D (4), T (1)
A2	8	-3.50/-3.50 ×5	R, 6/18	NA	P (4), D (3), T (2)
		-3.00/-4.00 ×180	L, 6/18	NA	OU
A3	67	-2.00/-3.00 ×10	R, 6/12	NA*	NA*
		-2.50/-2.50 ×120	L, 6/12	NA	NA
B1	18	-6.00/-2.00 ×15	R, 6/18	Protan	P (no), D (4), T (1)
		-6.00/-2.50 ×160	L, 6/18	Protan	P (no), D (4), T (2)
B2	22	-3.00/-3.00 ×25	R, 6/12	Protan	P (4), D (2), T (1)
		-2.50/-2.50 ×130	L, 6/12	Protan	P (no), D (3), T (0.5)
C1	7	-3.00/-2.50 ×30	R, 6/36	NA	P (4), D (3), T (2)
		-3.25/-1.25 ×165	L, 6/24		P (4), D (3), T (2)
C2	5	-2.00/-1.50 ×180	R, 6/12	NA	P (5), D (4), T (1)
		-2.00/-1.00 ×180	L, 6/12		P (5), D (4), T (1)
C3	4	-2.50/-2.25 ×180	R, 6/18	NA	NA
		-2.50/-2.25 ×180	L, 6/18		
D1	7	-4.75/-1.00 ×80	R, 6/24	Protan	P (no), D (3), T (0.5)
		-4.75/-1.00 ×120	L, 6/18		

Numbers in parentheses indicate the least saturated chip that could be discriminated from the neutral chips.

D = deutan axis; L = left eye; NA = not applicable; P = protan axis; R = right eye; T = tritan axis.

*A protan color vision defect on testing with Hardy, Rand, and Rittler plates.

Table 3. Nucleotide Differences between Middle (M) and Long (L) Exons Used for Opsin Gene Identification

L/M Opsin Exon	Nucleotide	L Sequence	M Sequence
2	194	C	T
	331	A	G
	347	C	A
3	457	C	A
	538	T	G
4	691	T	C
	699	G	A
	700	C	G
	701	T	C
	708	A	G
5	822	A	G
	825	T	C
	827	T	G
	830	G	A
	832	A	T
	837	G	T
	855	A	G
	890	T	C
	894	G	C
	928	A	T